

Acute Myocarditis and Pericarditis in Children

Hari Tunuguntla, MD, MPH,* Aamir Jeewa, MD,† Susan W. Denfield, MD*

*Department of Pediatrics, Division of Pediatric Cardiology, Texas Children's Hospital, Baylor College of Medicine, Houston, TX

†Department of Pediatrics, Hospital for Sick Children, Toronto, Ontario, Canada

Practice Gaps

1. The diagnoses of myocarditis and pericarditis are often delayed because they are uncommon diseases in pediatrics and because symptoms in the early stages may be overlooked in the context of current or recent viral illnesses or other systemic diseases. Early suspicion for and recognition of signs and symptoms, particularly of myocarditis, are important because the disease process can rapidly become life-threatening. Although pericarditis can also be life-threatening, it is less commonly so than myocarditis.
2. Clinicians should be aware of the predisposing factors and the clinical signs and symptoms that should increase the index of suspicion for these entities because prompt referral to the emergency department, with access to specialists with expertise in the care and support of these patients, is imperative.

Objectives After completing this article, readers should be able to:

1. Recognize the context in which myocarditis and pericarditis arise in a differential diagnosis.
2. Identify causes of myocarditis and pericarditis.
3. Recognize clinical signs and symptoms of myocarditis and pericarditis.
4. Appropriately refer patients to the emergency department for further evaluation.

AUTHOR DISCLOSURE Drs Tunuguntla, Jeewa, and Denfield have disclosed no financial relationships relevant to this article. This commentary does not contain a discussion of an unapproved/investigative use of a commercial product/device.

INTRODUCTION

Myocardial and pericardial diseases are uncommon problems in childhood that can present as isolated diagnoses or as part of systemic diseases. Although they can have the same etiologies, and symptoms often overlap, their prognosis and treatment differ significantly. It is important to make an accurate diagnosis because clinically apparent myocarditis is much more likely to be life-threatening, and rapidly so, than pericarditis. Children with suspected myocarditis or pericarditis should be sent to an emergency department, where access to specialists with expertise in these diseases is available. The key is early suspicion for these entities to make a timely referral and diagnosis and institute appropriate therapies and interventions.

ABBREVIATIONS

CMR	cardiovascular magnetic resonance imaging
DCM	dilated cardiomyopathy
ECG	electrocardiogram
EMB	endomyocardial biopsy
IVIg	intravenous immunoglobulin
MCS	mechanical circulatory support
PCR	polymerase chain reaction
PHIS	Pediatric Health Care Information System
VAD	ventricular assist device

MYOCARDITIS

Epidemiology

Myocarditis is an inflammatory disease of the myocardium due to a myriad of causes and resulting in variable degrees of myocardial dysfunction. The true incidence of myocarditis is likely underestimated because the disease can be subclinical or mild enough to go unrecognized in the context of a viral syndrome with multiple body aches and gastrointestinal and respiratory symptoms. Myocarditis is an uncommon diagnosis, accounting for 0.05% of pediatric admissions in a study using the Pediatric Health Care Information System (PHIS) database. (1) Although a small proportion of admissions, children with myocarditis were more likely to die than were children admitted with other diagnoses in that study. In a Finnish national registry study of children, the incidence of myocarditis was approximately 2 in 100,000 patient-years, with a male predominance in children older than 6 years. (2) There was no sex difference in the occurrence of myocarditis in children younger than 6 years.

In a large autopsy-based study of children (1,516 autopsies over 10 years, ages 10 days to 16 years), histologically proven myocarditis was present in approximately 2%. (3) Myocarditis accounted for 2% of infant deaths and 5% of deaths in children older than 5 years referred for autopsy. Sudden death was common, occurring in 57% in that study. When evaluated from a sudden death perspective, myocarditis accounts for approximately 5% to 6% of sudden deaths in young athletes in the United States. (4)(5) Myocarditis can also lead to the development of a chronic dilated cardiomyopathy (DCM), which is the leading cause of pediatric heart transplant in children older than 1 year. (6) Of children with a known cause for DCM, up to 46% have been reported to be due to myocarditis. (7) However, estimates of the percentage of DCMs caused by myocarditis vary, likely due to the variability in the way the diagnosis is established. Clinically it can be difficult to differentiate between a child who presents acutely in heart failure during or after an infectious illness and has an acute process due to the infection versus a child with a previously subclinical cardiomyopathy who has decompensated due to the additional metabolic stress of an infection. The gold standard for the diagnosis of myocarditis is histologic analysis on endomyocardial biopsy (EMB), but the diagnosis is often made based on other clinical studies and a compatible patient history.

Etiologies/Classification

Myocarditis can be classified based on etiology: infectious, immunologic, or toxic; histopathologically by cell infiltrate: eosinophilic, lymphocytic, granulomatous, giant cell, or

neutrophilic; or by clinical features: fulminant, acute, or subacute, including chronic active with persistent inflammation or chronic persistent without persisting inflammation. (8)(9) There are multiple causes of myocarditis, many of which are shown in the Table, in conjunction with causes of pericarditis, which often overlap. Despite the many known causes, the exact etiology remains undetermined in many patients. (9)(10)(11)

Viral infection is the most commonly identified cause of myocarditis in North America and Western Europe; rheumatic carditis, *Trypanosoma cruzi* (Chagas disease), and bacterial infections such as diphtheria are common in the developing world. (9)(11)

Historically, the enteroviruses, particularly the Coxsackie group B serotypes, have been implicated as the primary viral etiology. However, more recently, viral genomes from EMBs have shown parvovirus B19, human herpesvirus 6, and adenovirus to be increasingly common. Human immunodeficiency virus has also been associated with myocarditis. Overall, there are nearly 20 known cardiotropic viruses that can result in myocarditis. (8)

Myocarditis related to bacterial infection is less common in the United States. *Borrelia burgdorferi*, which causes Lyme disease, can cause acute and chronic myocarditis, although full recovery is usually expected. In a pediatric study of 207 children with disseminated Lyme disease, 16% had carditis, and 42% with carditis had advanced heart block. (12)

Chagas disease, which is caused by the protozoa *Trypanosoma cruzi*, is commonly seen in South and Central America and is becoming increasingly recognized in the United States. A pericardial effusion is often seen during the acute phase, while DCM and left ventricular apical aneurysms can be seen in the chronic phase. Conduction abnormalities can also occur. (9)(11)

Drugs can cause myocardial inflammation by a direct toxic effect or by a hypersensitivity reaction, with the latter resulting in eosinophilic infiltrates in the myocardium. Drug-induced hypersensitivity reactions, systemic diseases such as Churg-Strauss or hypereosinophilia syndrome, and parasitic infections should be considered in the presence of peripheral eosinophilia or eosinophilic myocardial infiltration on EMB. Idiopathic giant cell myocarditis is a rare, autoimmune form of myocarditis characterized by multinucleated giant cells on histopathologic analysis. It carries a high risk of mortality unless cardiac transplant is considered. (11) However, it may recur in the transplanted heart.

Pathogenesis

The pathophysiology of myocarditis has primarily been studied in the murine mouse model. There are 3 overlapping

phases: acute injury from the virus, injury related to the ensuing innate and acquired immunologic responses, and recovery, or transition to scar with DCM. (11)(13)

Acute injury often involves a viral trigger. Depending on the type of virus, different cardiac cells are affected. Parvovirus B19 (also called erythrovirus B19) and human herpesvirus 6 infect vascular endothelial cells as well as cardiomyocytes. Enteroviruses may cause a direct lytic infection of the cardiomyocyte. (11)(13)(14) Coxsackie B and adenoviruses enter the myocytes through a specific cardiac receptor called the Coxsackie and adenovirus receptor. The expression of Coxsackie and adenovirus receptor peaks in the perinatal period, which is the likely explanation for increased susceptibility in neonates, often resulting in a more fulminant presentation. Replication of the virus leads to myocyte necrosis, exposure of intracellular cardiac antigens, and activation of the host's immune system involving both cytokines and cell-mediated immunity responses. (11)(13)(14) Depending on the viral load and extent of ongoing host reaction, varying degrees of cardiac damage occur.

After the acute phase, occurring over days, a subacute phase ensues over weeks to months, mediated by the activated inflammatory cells and cytokines. In addition to attacking the virus, these responses can cause cardiac cells to lyse, inflicting further damage to the myocardium. Both T and B cells become activated which can cause an autoimmune response to cardiac cells and cell proteins. In the chronic phase there may be resolution of the infection and inflammatory response with complete recovery, or, depending on the degree of damage already inflicted, a chronic DCM may ensue. In the chronic form, the virus and the inflammatory response may or may not persist. (11)(13)(15)

Clinical Presentation

The clinical manifestations of myocarditis can range from having mild nonspecific symptoms to chest pain to cardiogenic shock. Presenting scenarios include acute heart failure of recent onset without cardiogenic shock, fulminant myocarditis with impending cardiovascular collapse, and at times malignant arrhythmias, myopericarditis resembling an acute coronary syndrome, sudden death, or an insidious onset of heart failure symptoms with chronic heart failure/DCM at presentation. (8)(15)

Children who present with heart failure symptoms in the nonfulminant form may present with shortness of breath, dyspnea with exertion, nausea, and decreased appetite, or poor feeding and tachypnea in infants, initially. These symptoms are often mistaken for other noncardiac-related illnesses or as part of a noncardiac viral syndrome. A history of a preceding infectious illness is common in many

patients presenting to an office, and most infections do not result in myocarditis; therefore, it does not come up high in the differential diagnosis. During the examination it is important to note the heart rate because it often seems disproportionately elevated compared with the overall appearance of the child. By the time of presentation to the emergency department patients commonly have respiratory distress, tachycardia, lethargy, a gallop rhythm, and hepatomegaly. (16) A common mistake on abdominal examination is to palpate for the liver starting near the costal margin. It is important to start in the pelvis and palpate up from there because if the liver is very enlarged the edge will not be felt near the costal margin and may be mistaken for normal sized, or nonpalpable. Absence of rales and peripheral edema in children with heart failure is quite common, and their absence is not reassuring. When obtained, the echocardiogram demonstrates left ventricular dilation and moderate to severe systolic dysfunction with normal- to thin-appearing walls.

The fulminant form of myocarditis is more common in children than in adults, with some studies reporting an increased likelihood of recovery compared with noninflammatory DCM. (6)(17) In the fulminant form it is easier to recognize that the children are critically ill, but it is not unusual for this form to be mistaken for sepsis or severe dehydration, with large volumes of fluid given, after which pulmonary edema and cardiovascular collapse may rapidly ensue, with subsequent recognition of cardiac dysfunction. These children typically present looking very ill, with cold extremities, weak peripheral pulses, a gallop rhythm, and hepatomegaly being more common than rales and edema. Multiorgan system dysfunction or failure is common. Malignant arrhythmias may also occur. In these cases, on echocardiogram there is severely depressed left ventricular systolic function with usually a normal-sized left ventricle with relatively thick myocardium, which may be due to myocardial edema. (8)(9)(15)

Myocarditis can mimic an acute coronary syndrome. This presentation is more common in adolescents who present with symptoms of chest pain, electrocardiographic (ECG) changes suggesting ischemia, and elevated troponin levels. (15) Boys with Duchenne muscular dystrophy are particularly susceptible to myocarditis (especially enteroviral). (18) If a patient with Duchenne muscular dystrophy presents with chest pain, the clinician needs to have a high index of suspicion for myocarditis and evaluate accordingly. Differentiating between an acute myocardial infarction and myocarditis can be challenging, but myocarditis is more likely in the pediatric population. Clinicians should consider a diagnosis of acute myocarditis in younger patients without

coronary risk factors, ECG abnormalities extending beyond the distribution of a single coronary artery territory, and global ventricular dysfunction on echocardiography. (8)(19) With this presentation, ventricular dysfunction tends to be mild, with most recovering completely over variable time frames.

Myocarditis can result in life-threatening arrhythmias and conduction abnormalities, including variable degrees of atrioventricular block, ventricular fibrillation/flutter, or ventricular tachycardia. Myocarditis can cause sudden cardiac death, with no symptoms until death. (8)

Myocarditis may progress to a “burned out” phase. Patients in this chronic phase typically have a more gradual progression of heart failure symptoms, and in retrospect the family recognizes that the symptoms have been building over several months. It is often difficult to differentiate chronic myocarditis from other causes of DCM. (8)

Diagnosis

After a thorough patient and family history and physical examination, the evaluation of patients with suspected myocarditis begins with biomarkers, ECG, chest radiography, and echocardiography.

Elevated cardiac biomarkers such as creatine kinase muscle-brain isoenzyme, troponin I, and troponin T confirm the diagnosis of cardiac injury. Troponin I and T levels are more frequently elevated in acute myocarditis than are creatine kinase muscle-brain levels. (11)(13)(19) Troponin T is reported to have specificity of 86% and sensitivity of 71% in children. (20) However, normal biomarker levels do not completely exclude myocarditis. The diagnostic value of viral serologies remains unclear because they may not correlate with the virus found on EMB, if performed, and serial serologies are needed. Moreover, many of the cardiotropic viruses are prevalent in the population at large and may be “innocent bystanders.” (13) Viral polymerase chain reaction (PCR) of the blood or respiratory tract for common cardiotropic viruses are likely more useful than serologies, but the absence of a positive PCR does not exclude a viral cause because the viremic phase may have resolved before cardiac manifestations.

The ECG is usually abnormal. Nonspecific findings, including sinus tachycardia, ST- and T-wave abnormalities at times mimicking ischemia, and low-voltage QRS complexes, especially in the limb leads, may be seen. Figure 1 illustrates these points, with arrows pointing to the P wave and the QRS complex in lead II and the ST segment in V_5 in a patient with parvovirus myocarditis. The P wave is actually larger than the tiny QRS. The QRS complexes are barely discernable in limb leads I through aVL. The ST segments

are markedly elevated in leads V_2 through V_7 . Atrial or ventricular conduction delays and supraventricular or ventricular arrhythmias can occur. The presence of a Q wave or widened QRS (neither are demonstrated in Fig 1) may be associated with a worse prognosis. (9) Normal values for the QRS duration vary with age. The normal QRS duration is typically 70 to 85 milliseconds in neonates and 90 to 110 milliseconds in adolescents. (21)

Chest radiography may demonstrate cardiomegaly due to pericardial effusion or dilation of the cardiac chambers. Pulmonary edema, pulmonary venous congestion, and pleural effusions may also be seen.

There are no specific features of myocarditis on echocardiography. However, it is a valuable tool in ruling out other anatomical/structural causes of heart failure, evaluating systolic and diastolic function, cardiac chamber sizes, and wall thicknesses and identifying the presence of a pericardial effusion.

Cardiovascular magnetic resonance imaging (CMR) is becoming a routine, noninvasive tool in the assessment of myocarditis. The International Consensus Group on CMR recommends that CMR be performed in patients with a clinical suspicion for myocarditis in whom the results will affect clinical management. Although clinical management is largely supportive, some centers may use immunomodulating therapies (see the “Treatment” subsection) if their clinical suspicion for myocarditis is high. The Lake Louise criteria established the CMR criteria of myocarditis, and when 2 or more of the criteria are present it can predict myocardial inflammation with 78% accuracy. (11) Usually CMR requires general anesthesia in young children, which can pose a significant risk in a critically ill child and can limit its use, particularly because CMR findings do not usually result in a change of therapies.

Endomyocardial biopsy is considered the gold standard for the diagnosis of myocarditis. The Dallas criteria, which were published in 1987, define the histopathologic classification for myocarditis. (22) These criteria require that there is an inflammatory cellular infiltrate with myocyte necrosis not characteristic of ischemia. Borderline myocarditis is defined as the presence of an inflammatory infiltrate without myocyte necrosis on light microscopy. (13)(19)(22) The type of inflammatory cell infiltrate may guide the understanding of the etiology and therapy. The Dallas criteria are limited by their low sensitivity in part due to sampling error, as myocarditis can have a patchy infiltrate resulting in biopsy of areas that do not manifest disease. In addition, interobserver interpretation is variable. Biopsies generally lack prognostic value, except in isolated cases, such as giant cell myocarditis, which is very rare in children,

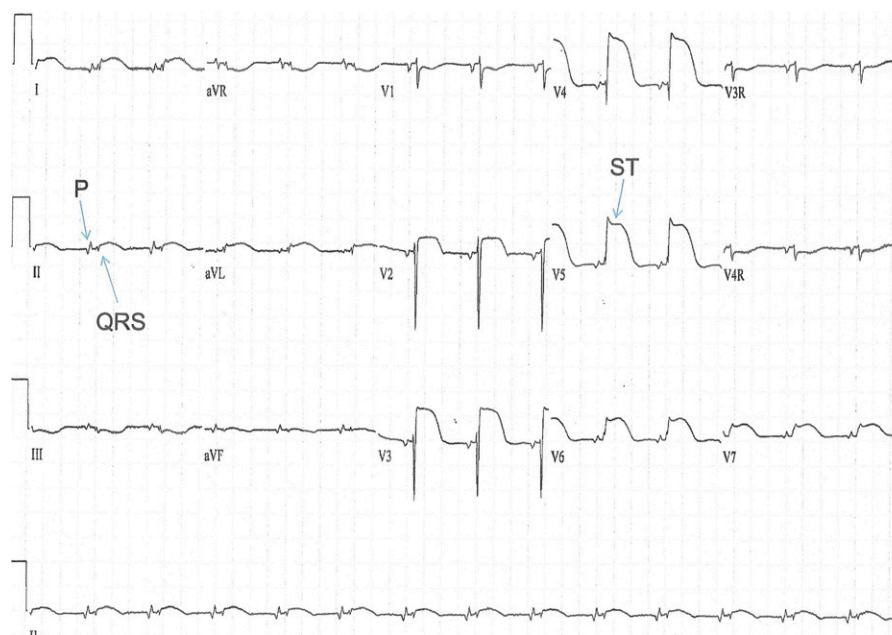


Figure 1. Electrocardiogram from a child with parvovirus myocarditis demonstrating very-low-voltage QRS complexes in leads I through aVF, V₁, V₄ through V₇, V_{3R}, and V_{4R}, as well as ST elevation most marked in V₂ through V₇. This appearance is called “tombstoning.” The P waves are actually larger than the QRS complexes in leads I through aVF.

but has a particularly poor prognosis. More recent histologic criteria include the use of immunoperoxidase stains of cell-specific surface antigens. (8)(11)(23) A consensus statement formulated by cardiac experts in 2007 recommends that EMB be reserved for patients with fulminant or acute DCM who develop sustained or symptomatic ventricular tachycardia or high-degree heart block, who fail to respond to standard heart failure therapies, or in individuals with systemic disease known to cause left ventricular dysfunction. (24) In practice, EMB is used when it is thought to offer prognostic and therapeutic value that outweighs the potential risks. (11)(19)

Treatment

Treatment of myocarditis depends on the clinical scenario, with supportive care being the first line. Patients with fulminant or acute myocarditis often require intubation with ventilator support and usually hemodynamic support with vasopressors, inotropes, and intravenous diuretics. Patients with refractory cardiogenic shock may require mechanical circulatory support (MCS) by either extracorporeal membrane oxygenation or a ventricular assist device (VAD). Extracorporeal membrane oxygenation, which is a temporary means of MCS, may be beneficial in patients with fulminant myocarditis, as recovery in the short term is anticipated. Patients with acute myocarditis may have a more prolonged recovery and may require a VAD as a bridge to cardiac transplant or recovery. The VADs do not have a

membrane oxygenator; the cardiovascular system is supported by the device, but the respiratory system is not. To be supported in this manner the patient must have an adequate respiratory status to be supported on a ventilator or be breathing spontaneously without ventilatory support. Heart failure refractory to optimal medical therapy or dependence on MCS may necessitate cardiac transplant. (11)(13)(19) The advantage of VAD support is that, depending on the device, patients can be supported for months to years and can be discharged home, even returning to school with these devices in place, while awaiting heart transplant or recovery.

Once hemodynamic stability is achieved, standard heart failure therapy, including angiotensin-converting enzyme inhibitors or angiotensin receptor antagonists, β -blockers, and spironolactone, should be implemented. Antiarrhythmic medications and placement of a temporary or permanent pacemaker may be required for tachyarrhythmias and high-grade atrioventricular block, respectively. An implantable cardioverter-defibrillator may be considered if ventricular arrhythmias persist after the acute inflammatory phase. (11)(13)

Numerous studies have investigated the use of immunosuppression in acute myocarditis with varying outcomes. The Myocarditis Treatment Trial randomized 111 adults with biopsy-proven myocarditis to receive placebo or an immunosuppressive regimen of prednisone and cyclosporine or azathioprine. (25) No difference in mortality or improvement in left ventricular ejection fraction was seen between the groups. Routine use of immunosuppressive drugs in

viral or lymphocytic myocarditis is not recommended in adults; however, some centers continue to use these agents in adults and children. The use of immunosuppression can be helpful in treating myocarditis due to systemic autoimmune diseases, idiopathic giant cell myocarditis, and eosinophilic myocarditis. (13)(19)

Studies evaluating the efficacy of intravenous immunoglobulin (IVIg) also show variable results. A small case series in a pediatric population with acute myocarditis demonstrated benefit in using IVIg. (26) In a more recent retrospective pediatric study, neither IVIg nor corticosteroids individually or combined demonstrated any benefit in myocarditis. (27) In a study of adults with less than 6 months of symptoms, there was no difference in ejection fraction at 6 and 12 months between the IVIg-treated group and the control group. (28) Currently, the use of IVIg in suspected myocarditis varies between pediatric centers. (1)

If a specific viral etiology is found for which there are antiviral therapies (eg, cytomegalovirus, herpesviruses, and influenza), then specific antiviral therapy is indicated. The development of highly active antiretroviral therapy has decreased the incidence of human immunodeficiency virus-associated myocarditis. (11)

Regarding long-term treatment, oral heart failure therapies are continued as long as there is ongoing cardiac dysfunction. In the event of complete recovery the therapies may be weaned after a period of well-established normalization of function and absence of significant tachyarrhythmias. Strenuous physical activity, including physical education classes, should be avoided for at least 6 months in patients with probable or definite myocarditis. Returning to participation in competitive sports can be considered 6 months after the initial illness if the ventricular function and markers of myocardial injury, inflammation, and heart failure have normalized, and there is no evidence of clinically relevant arrhythmias on 24-hour ambulatory ECG monitoring and exercise testing. (5)

Outcome

The prognosis for individuals with myocarditis is as variable as the clinical presentation. Patients with acute myocarditis and normal cardiac function have a good prognosis overall, with a high likelihood for spontaneous recovery. Those with fulminant viral myocarditis are more likely to have recovery if adequately supported with medications or MCS during the initial phase. Giant cell myocarditis has a poor prognosis in both children and adults, with median survival of less than 6 months without cardiac transplant. (11)(13)

In a study of a multicenter cohort of 171 pediatric patients with myocarditis, 13% died or underwent cardiac transplant

during their initial hospitalization. (27) In a large cohort of pediatric patients with DCM from the Pediatric Cardiomyopathy Registry, myocarditis was the most common known cause of DCM. For those with an underlying etiology of myocarditis, freedom from transplant or death at 5 years after diagnosis was 73%. (7) In contrast, 50% of those with a DCM without known myocarditis had died or undergone cardiac transplant by 5 years after diagnosis. (7)

Although progress has been made in our understanding and supportive care of children with myocarditis, ongoing efforts are required to create targeted therapies to prevent the short- and long-term consequences of this disease.

PERICARDITIS

As opposed to myocarditis that primarily affects the myocardium, pericarditis primarily affects the pericardial layers overlying the heart. The pericardium consists of 2 main layers and serves as a structural barrier to protect the heart from dissemination of infectious, inflammatory, and neoplastic diseases. (29) Typically, a small amount of serous fluid is present between the layers to provide lubrication. Irritation or inflammation of the pericardial layers, acutely or chronically, results in pericarditis.

Epidemiology

Pericarditis is the most common form of pericardial disease and has a broad range of etiologies that vary with age and geographic location (Table). (30) The true incidence of pericarditis is difficult to ascertain because asymptomatic or minimally symptomatic episodes are likely undetected, similar to mild forms of myocarditis. A large Finnish national registry study of inpatients found that of those aged 16 to 20 years, 4% of all cardiovascular admissions to hospitals were secondary to pericarditis. (31) In a US-based study of hospitalized children, using the PHIS database, of the 11,364 admissions with a diagnosis code of pericardial effusion, approximately 5% were diagnosed as having idiopathic or viral pericarditis. (32) Pericarditis was most common in adolescent males, a predilection also reported in the Finnish study. (31)

Etiologies

The common infectious etiologies of pericarditis vary geographically. In Europe and North America, viral or postviral etiologies are more common, whereas in regions where tuberculosis remains prevalent, up to 70% of cases are tuberculosis related (Table). (30) Although most viral or idiopathic pericarditis is not life-threatening, bacterial pericarditis frequently is serious and life-threatening. (31)

TABLE. Causes of Myocarditis and/or Pericarditis in Children

INFECTIOUS MYOCARDITIS (M) AND PERICARDITIS (P)	NONINFECTIOUS MYOCARDITIS AND PERICARDITIS
Viral	Autoimmune
• Enteroviruses such as echovirus and Coxsackie virus	• Postpericardiotomy syndrome (P)
• Influenza	• Systemic lupus erythematosus
• Epstein-Barr virus and cytomegalovirus	• Kawasaki disease
• Adenovirus	• Juvenile idiopathic arthritis (P>>M)
• Parvovirus B19	• Churg-Strauss
• Varicella	
• Mumps	Neoplastic – pericarditis
• Rubella	• Sarcomas
• Hepatitis viruses	• Lymphomas
• Human immunodeficiency virus	
• Human herpesvirus 6	Metabolic – pericarditis
Bacterial	• Uremia
• Tuberculosis	• Myxedema
• <i>Coxiella burnetti</i>	
• Pneumococcus	Trauma – pericarditis
• Meningococcus	• Radiation (may cause pancarditis)
• Staphylococci	• Direct injury includes blunt chest trauma
• Hemophilus	
• Legionella	Drug exposure/hypersensitivity reactions
• Listeria	• Tetracyclines
• Leptospira	• Sulfonamides
• <i>Borrelia burgdorferi</i> (Lyme disease)	• Penicillins
• Streptococcus	
• <i>Corynebacterium diphtheriae</i>	
Fungal (important in immunocompromised hosts)	
• Histoplasma	
• Aspergillosis	
• Candida	
• Blastomycosis	
Protozoal	
• Toxoplasma	
• <i>Trypanosoma cruzi</i> (Chagas disease)	

Adapted with permission from Imazio M, Spodick DH, Brucato A, Trincherò R, Markel G, Adler Y. Diagnostic issues in the clinical management of pericarditis. *Int J Clin Pract.* 2010;64(10):1384–1392. Copyright © 2010 by John Wiley & Sons Inc.

Bacterial pericarditis is more common in children younger than 2 years. (29)

Regarding noninfectious etiologies in children, there may be a higher preponderance of post-cardiac surgery-associated pericarditis compared with other systemic etiologies. (32)(33) In children who have recently undergone cardiac surgery, an effusion may develop due to an entity called *postpericardiotomy syndrome*. Additional well-described etiologies in children include rheumatologic diseases, some cancers and their associated radiation or chemotherapies, and renal failure.

Pathophysiology

When the pericardium becomes inflamed there is typically an accompanying increase in pericardial fluid, resulting in a collection large enough to be classified as a pericardial effusion. Although not common, life-threatening cardiac tamponade can occur depending on the size of the effusion and the rapidity with which it develops. This occurs because of the inability of the ventricles to fill adequately due to the pericardial fluid compressing the heart, which can culminate in cardiovascular collapse. A relatively small effusion can result in tamponade physiology if it accumulates quickly, while a very large effusion may not cause tamponade if it increases slowly. Depending on the underlying etiology of pericarditis, the fluid may be a transudate or an exudate.

However, it is also possible to have pericarditis in the absence of a significant pericardial effusion. The inflamed pericardium may also cause subjacent inflammation of the superficial myocardium, which then results in the ECG changes seen in pericarditis.

Clinical Presentation

In acute pericarditis, a history of a current or recent viral syndrome is common. The classic symptom is chest pain that is relieved in the sitting position and exacerbated when supine, coughing, or with inspiration. (29) It can be associated with fever, particularly in cases of bacterial pericarditis. The physical examination findings may be normal or may demonstrate a precordial friction rub on auscultation, which has been described as scratchy or “creaking leather” and augmented by sitting or inspiration. In cases that develop a large pericardial effusion, the heart sounds may be muffled in addition to the friction rub; however, a rub may be absent in this circumstance as well. Patients are frequently tachycardic. Neck vein distention and a decrease in peripheral pulses during inspiration, or pulsus paradoxus, may be elicited in patients with a hemodynamically significant pericardial effusion. These patients typically

appear very anxious and resist lying down. However, the clinical presentation spans the spectrum from mild discomfort to the appearance of impending shock with cardiovascular collapse, the latter being less common.

Diagnosis

The initial diagnostic testing for pericarditis typically includes chest radiography; however, it is not uncommon for the cardiac silhouette and pulmonary vascular markings to be normal. In the setting of a pericardial effusion with pericarditis, the heart size may be enlarged due to the distention of the pericardial sac, often without pulmonary edema. The chest radiograph may also provide some insight into the underlying cause, such as in the case of malignancy with mediastinal involvement. The ECG changes are not always specific for pericarditis. The most common abnormality seen is diffuse ST-segment elevation in the precordial leads of the ECG without T-wave inversion in the acute phase and PR-interval depression. The ST-segment changes need to be differentiated from benign early repolarization seen in children and adolescents and myocardial infarction, which is rare in children. Similar to ECG in myocarditis, the ST-segment elevation does not follow a typical coronary distribution pattern, being more diffuse (Fig 2).

A transthoracic echocardiogram is performed to help distinguish pericarditis from myocarditis, in which there is usually cardiac dysfunction as opposed to pericarditis in which the function is normal. The echocardiogram establishes the presence and size of a pericardial effusion. Cardiac computed tomography and magnetic resonance imaging are not typically needed in acute pericarditis. These modalities may be indicated in more complicated recurrent or chronic forms, or if there is concern for constrictive pericarditis, which has a much worse prognosis and is even less common than acute pericarditis.

The laboratory findings of pericarditis are somewhat dependent on the underlying etiology. Elevations in white blood cell count, erythrocyte sedimentation rate, and other acute-phase reactants can be seen in infectious cases but may also be present in systemic autoimmune disorders and some malignancies. Troponin elevations occur in approximately one-third of patients with pericarditis, consistent with some degree of mild myocardial inflammation, which can occur subjacent to the pericardial inflammation. This often raises concern for an acute coronary syndrome, especially in conjunction with ST-segment elevation on ECG, particularly if the patient does not present to a children’s hospital. The age of the patient and the diffuse ST changes make the diagnosis of a myocardial infarction less likely

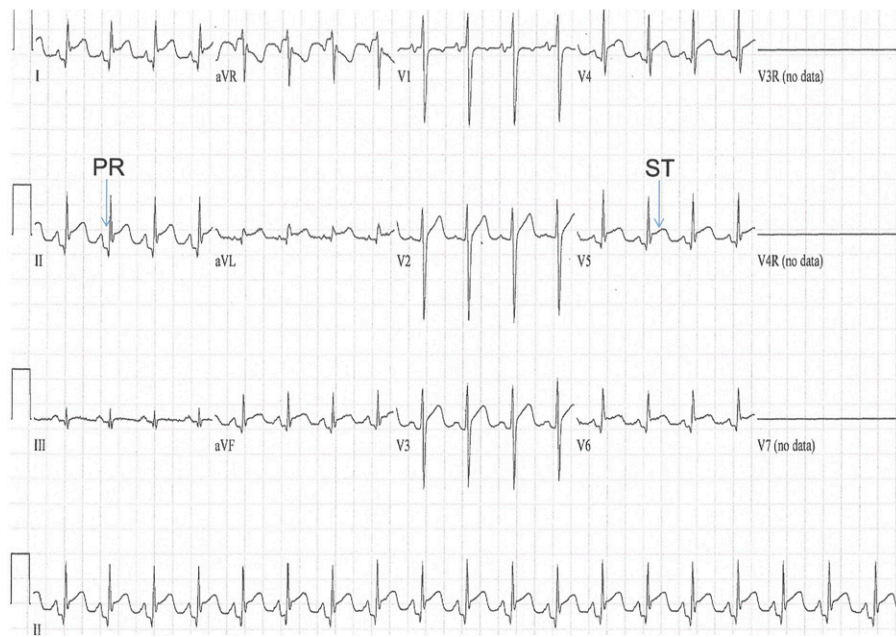


FIGURE 2. Electrocardiogram from an adolescent with pericarditis. The PR depression is most evident in leads I, II, aVF, and V₄ through V₆. The ST elevation is most prominent in leads I, II, aVL, aVF, and V₂ through V₆.

than pericarditis. Testing for infectious causes can be helpful for determining an etiology. If pericardiocentesis is performed, fluid should be sent for cultures and PCR as well as cell count, cytology, and biochemical markers.

Treatment

Nonsteroidal anti-inflammatory drugs are the basis of therapy for acute pericarditis in children. A multicenter cohort study in children with recurrent pericarditis by Imazio et al demonstrated a decrease in the recurrence of pericarditis when treated with colchicine as well. (34) Conversely, the use of corticosteroids was associated with an increased risk of recurrences in children and adults. (34)(35) In adults, guidelines recommend the initial use of a nonsteroidal anti-inflammatory drug with colchicine to reduce the recurrence risk. It is recommended that corticosteroids be avoided due to their increased risk of adverse effects and recurrences, unless there is a specific indication due to a systemic, usually autoimmune, disease that requires corticosteroid use. (35) There are novel immunomodulating therapies involving blockade of the interleukin-1 receptors (anakinra) that have been used with promising results in refractory cases of pericarditis. (36) In the setting of pericarditis with a large pericardial effusion or with signs of cardiac tamponade, pericardiocentesis can be both therapeutic and diagnostic. This procedure was performed in approximately 14% of pediatric patients with viral or idiopathic pericarditis in the PHIS database study by

Shakti et al. (32) In particularly refractory cases, surgical pericardiectomy and pericardiectomy are options. Surgical pericardiectomy or pericardiectomy was performed in approximately 4% of pediatric patients in the study by Shakti et al. (32)

It is recommended that strenuous physical activities should be avoided for a minimum of 3 months after the onset of symptoms. (37) Before returning to strenuous activities, the patient should be symptom free, with normal inflammatory markers and biomarkers and normal ECG and echocardiography findings.

Outcomes

Most cases of idiopathic or viral pericarditis resolve without further sequelae. No deaths were reported in the study by Shakti et al of the PHIS database. (32) Recurrent pericarditis was reported in approximately 10% of children. The risk of death changes with the etiology, however. The risk of death is much higher in bacterial pericarditis, especially in those instances that go without treatment. (29)(31) Rarely, a constrictive form of pericarditis may develop. Constrictive pericarditis usually has an insidious presentation, typically with ascites and hepatomegaly as significant features. Unlike the acute forms of pericarditis, pericardiectomy is likely to be required and the prognosis is considerably worse. The association of pericarditis with malignancy or other systemic diseases also changes outcomes as relates to the underlying disease.

Summary

Myocarditis and pericarditis are uncommon diseases of childhood, both commonly caused by cardiotropic viruses, based on database, registry, and case series/cohort studies.(1)(2)(10)(28)(29)(30)

Treatment of myocarditis is largely supportive, based on expert opinion, per a position statement by the European Society of Cardiology Working Group on Myocardial and Pericardial Diseases.

(10) Pericarditis typically responds well to nonsteroidal anti-inflammatory drugs and colchicine, based on adult studies and guidelines and a multicenter cohort study in children.(32)(33)

Corticosteroids, unless specifically indicated for a systemic, usually

autoimmune, disease, should be avoided.(32)(33) Myocarditis has a much more malignant course, with a significantly higher mortality risk than pericarditis.(7)(25)(30) Based on expert opinion, timely recognition and early referral to emergency departments with access to specialists with expertise in these diseases is necessary to maximize outcomes as much as possible.

References for this article are at <http://pedsinreview.aappublications.org/content/40/1/14>.

PIR Quiz

There are two ways to access the journal CME quizzes:

1. Individual CME quizzes are available via the blue CME link under the article title in the Table of Contents of any issue.
2. To access all CME articles, click "Journal CME" from Gateway's orange main menu or go directly to: <http://www.aappublications.org/content/journal-cme>.
3. To learn how to claim MOC points, go to: <http://www.aappublications.org/content/moc-credit>.

1. A previously healthy 5-month-old girl is seen in the emergency department with a 3-day history of poor feeding and worsening decreased activity. Her parents have also noted her to be breathing faster. She has not had diarrhea or vomiting. She had a febrile illness with a rash 7 days ago that resolved after 2 to 3 days. She is toxic appearing and grunting. Her temperature is 102.2°F (39.0°C), heart rate is 186 beats/min, respiratory rate is 45 breaths/min, and oxygen saturation is 91% on room air. Cardiac examination shows no murmur, but a gallop rhythm is heard. There is evidence of subcostal and intercostal retractions, but no wheezing or rales are heard on lung examination. Her liver is 5 cm below the right costal margin. There is no peripheral edema. Creatinine kinase and troponin levels are elevated. An electrocardiogram (ECG) shows sinus tachycardia with diffuse ST elevation. An echocardiogram is most likely to show which of the following findings?
 - A. Left ventricular dilation with severe systolic dysfunction.
 - B. Normal biventricular cardiac contractility with biventricular myocardial thickening.
 - C. Right ventricular hypertrophy with normal right ventricular size.
 - D. Right ventricular dilation with right ventricular hypertrophy and normal left ventricular systolic function.
 - E. Thick myocardium and a normal-sized left ventricle.
2. A 12-year-old boy with Duchenne muscular dystrophy is hospitalized with a 2-day history of chest pain. An ECG shows diffuse ST elevation with no Q waves. Chest radiography shows cardiomegaly but no focal pulmonary infiltrates. An echocardiogram shows no pericardial effusion and moderate systolic dysfunction. Which of the following is the most likely etiology for this acute illness in this patient?
 - A. Anomalous coronary artery.
 - B. *Aspergillus fumigatus*.
 - C. Enterovirus.
 - D. Hemophilus influenza type B.
 - E. *Toxoplasma gondii*.
3. A previously healthy 3-year-old girl is seen in the emergency department with a 5-day history of increasing shortness of breath, dyspnea with exertion, and decreased appetite. She recently recovered from acute viral gastroenteritis. A chest radiograph shows normal lung fields, but cardiac size is mildly increased. Elevation of which of the following laboratory results would be most specific for the diagnosis of myocarditis?
 - A. Brain natriuretic peptide.
 - B. C-reactive protein.
 - C. Creatinine kinase.
 - D. Erythrocyte sedimentation rate.
 - E. Troponin T.

REQUIREMENTS: Learners can take *Pediatrics in Review* quizzes and claim credit online only at: <http://pedsinreview.org>.

To successfully complete 2019 *Pediatrics in Review* articles for *AMA PRA Category 1 Credit™*, learners must demonstrate a minimum performance level of 60% or higher on this assessment. If you score less than 60% on the assessment, you will be given additional opportunities to answer questions until an overall 60% or greater score is achieved.

This journal-based CME activity is available through Dec. 31, 2021, however, credit will be recorded in the year in which the learner completes the quiz.



2019 *Pediatrics in Review* now is approved for a total of 30 Maintenance of Certification (MOC) Part 2 credits by the American Board of Pediatrics through the AAP MOC Portfolio Program. Complete the first 10 issues or a total of 30 quizzes of journal CME credits, achieve a 60% passing score on each, and start claiming MOC credits as early as October 2019. To learn how to claim MOC points, go to: <http://www.aappublications.org/content/moc-credit>.

4. A previously healthy 16-year-old boy presents to the emergency department with his parents because of a sudden onset of sharp chest pain today. He had the “flu” the past week. The pain is improved by sitting up and leaning forward. It is worse with deep inspiration. He is in mild distress. Vital signs are within normal limits. Heart sounds are normal except for a friction rub heard when sitting up. The remainder of his examination findings are normal. A chest radiograph is normal. An ECG shows ST elevation in several precordial and limb leads, particularly in those representing the left ventricle. T waves are not inverted. Troponin level is normal. Which of the following is the most appropriate next step in diagnostic testing in this patient?
- A. Cardiac computed tomography.
 - B. Cardiac magnetic resonance imaging.
 - C. Computed tomography pulmonary angiogram.
 - D. D-dimer level.
 - E. Transthoracic echocardiogram.
5. For the same patient as in question 4, the diagnostic test performed confirmed the presence of normal cardiac function. Which of the following is the most appropriate next step in treatment?
- A. Anakinra.
 - B. Ibuprofen.
 - C. Intravenous immunoglobulin.
 - D. Intravenous methylprednisolone.
 - E. Oral prednisone.

Acute Myocarditis and Pericarditis in Children
Hari Tunuguntla, Aamir Jeewa and Susan W. Denfield
Pediatrics in Review 2019;40;14
DOI: 10.1542/pir.2018-0044

Updated Information & Services

including high resolution figures, can be found at:
<http://pedsinreview.aappublications.org/content/40/1/14>

References

This article cites 35 articles, 18 of which you can access for free at:
<http://pedsinreview.aappublications.org/content/40/1/14.full#ref-list-1>

Subspecialty Collections

This article, along with others on similar topics, appears in the following collection(s):
Medical Education
http://classic.pedsinreview.aappublications.org/cgi/collection/medical_education_sub
Journal CME
http://classic.pedsinreview.aappublications.org/cgi/collection/journal_cme
Cardiology
http://classic.pedsinreview.aappublications.org/cgi/collection/cardiology_sub
Cardiovascular Disorders
http://classic.pedsinreview.aappublications.org/cgi/collection/cardiovascular_disorders_sub

Permissions & Licensing

Information about reproducing this article in parts (figures, tables) or in its entirety can be found online at:
<https://shop.aap.org/licensing-permissions/>

Reprints

Information about ordering reprints can be found online:
<http://classic.pedsinreview.aappublications.org/content/reprints>



Acute Myocarditis and Pericarditis in Children

Hari Tunuguntla, Aamir Jeewa and Susan W. Denfield

Pediatrics in Review 2019;40;14

DOI: 10.1542/pir.2018-0044

The online version of this article, along with updated information and services, is located on the World Wide Web at:

<http://pedsinreview.aappublications.org/content/40/1/14>

Pediatrics in Review is the official journal of the American Academy of Pediatrics. A monthly publication, it has been published continuously since 1979. Pediatrics in Review is owned, published, and trademarked by the American Academy of Pediatrics, 345 Park Avenue, Itasca, Illinois, 60143. Copyright © 2019 by the American Academy of Pediatrics. All rights reserved. Print ISSN: 0191-9601.

American Academy of Pediatrics

DEDICATED TO THE HEALTH OF ALL CHILDREN®

