

# Hypoplastic Left Heart Syndrome: An Overview for Primary Care Providers

Rabia Javed, MBBS,\* Frank Cetta, MD,\*<sup>†‡</sup> Sameh M. Said, MD,<sup>§</sup> Timothy M. Olson, MD,\*<sup>†‡</sup> Patrick W. O'Leary, MD,\*<sup>†‡</sup> Muhammad Yasir Qureshi, MBBS\*<sup>†</sup>

\*Wanek Family Program for Hypoplastic Left Heart Syndrome; <sup>†</sup>Division of Pediatric Cardiology, Department of Pediatric and Adolescent Medicine; <sup>‡</sup>Department of Cardiovascular Medicine; <sup>§</sup>Department of Cardiovascular Surgery, Mayo Clinic, Rochester, MN

## Education Gaps

Primary care clinicians should be aware of the physiology of palliation in patients with hypoplastic left heart syndrome. These are patients with complex physiology after staged cardiac operations, and it is often challenging to treat them when they present with other illnesses.

## Objectives

After reading this article, readers should be able to:

1. Define hypoplastic left heart syndrome.
2. Discuss the current surgical strategies based on staged palliation.
3. Review the physiology of functional single-ventricle circulation in these patients.
4. Evaluate and treat common illnesses in patients at different stages of palliation.

## Abstract

Hypoplastic left heart syndrome is one of the most complex congenital heart diseases and requires several cardiac surgeries for survival. The diagnosis is usually established prenatally or shortly after birth. Each stage of surgery poses a unique hemodynamic situation that requires deeper understanding to manage common pediatric problems such as dehydration and respiratory infections. Careful multidisciplinary involvement in the care of these complex patients is improving their outcome; however, morbidity and mortality are still substantial. In this review, we focus on the hemodynamic aspects of various surgical stages that a primary care provider should know to manage these challenging patients.

**AUTHOR DISCLOSURE** Drs Javed, Cetta, Said, Olson, O'Leary, and Qureshi have disclosed no financial relationships relevant to this article. This commentary does contain a discussion of an unapproved/investigative use of a commercial product/device.

### ABBREVIATIONS

HLHS	hypoplastic left heart syndrome
IVC	inferior vena cava
LV	left ventricle
MBTS	modified Blalock-Taussig shunt
PA	pulmonary artery
PDA	patent ductus arteriosus
PGE1	prostaglandin E1
RV	right ventricle
RSV	respiratory syncytial virus
SVC	superior vena cava

## INTRODUCTION

Hypoplastic left heart syndrome (HLHS) is a congenital heart defect categorized as a form of functional single ventricle. It consists of a spectrum of anatomical variants characterized by underdevelopment of the left side of the heart. In HLHS, the right ventricle (RV) perfuses both systemic and pulmonary circulations, and the oxygenated blood bypasses the poorly developed left side of the heart through an atrial-level defect and patent ductus arteriosus (PDA). The management strategy for HLHS consists of a series of cardiac operations that culminate in the RV pumping blood to the systemic circulation, while the pulmonary blood flow is provided by passive flow from the superior vena cava (SVC) and inferior vena cava (IVC). Despite the many advances in diagnostic and management strategies in the past 3 decades, patients with HLHS continue to experience major morbidity and mortality. (1)

## GENETICS AND EPIDEMIOLOGY

HLHS accounts for 1.4% to 4.1% of all congenital heart diseases, with a prevalence rate of 2 to 3 cases per 10,000 live births in the United States. (2)(3)(4) There is a male predominance, with a reported male to female ratio of 3:2. (5) HLHS is thought to have a complex heterogeneous genetic basis. Specific genes associated with HLHS include *GJA1* (Connexin protein 43), *NKX2-5*, *NOTCH1*, *MYH6*, and *ERBB4*. (6)(7) HLHS has been associated with several syndromes, including Jacobsen (terminal deletion of the long arm of chromosome 11), Turner (monosomy X), Edwards (trisomy 18), Patau (trisomy 13), Noonan, Kabuki, Smith-Lemli-Opitz, Holt-Oram, oral-digital-facial, CHARGE (coloboma, heart anomalies, choanal atresia, retardation of growth and development, and genital and ear anomalies) association, and PAGOD (pulmonary hypoplasia, hypoplasia of pulmonary artery, agonadism, omphalocele/diaphragmatic defect, dextrocardia). (8)(9) A genetic association of HLHS with other left-sided obstructive lesions, such as bicuspid aortic valve, coarctation of aorta, Shone complex, and aortic valve stenosis, has been reported. (10)(11)

The recurrence risk of HLHS in families with 1 affected child is approximately 0.5% to 2%. The risk of other congenital malformations in first-degree family members has been reported to range from 10% to 17%. This highlights the importance of performing echocardiographic screening of all first-degree family members of patients with HLHS. (12)(13)(14) This also signifies the requirement of fetal echocardiography if the previous child in the family was diagnosed as having HLHS. In a recent study from Mayo

Clinic, familial screening of patients with HLHS found that 11% of 152 first-degree relatives had congenital cardiovascular malformations, of which 65% were undiagnosed before screening echocardiography. (13) Collectively, 27% of patients with HLHS had 1 or more siblings or parents with a congenital heart defect, most commonly bicuspid aortic valve or aortic root dilation.

## EMBRYOLOGY AND PATHOGENESIS

In a normal fetus, oxygenated blood from the placenta enters the right atrium via the umbilical vein and ductus venosus. Most of this oxygenated blood (60%) crosses the foramen ovale to reach the left atrium, bypassing the pulmonary circulation. This oxygenated blood is then delivered to the systemic circulation through the aorta, thereby perfusing the brain.

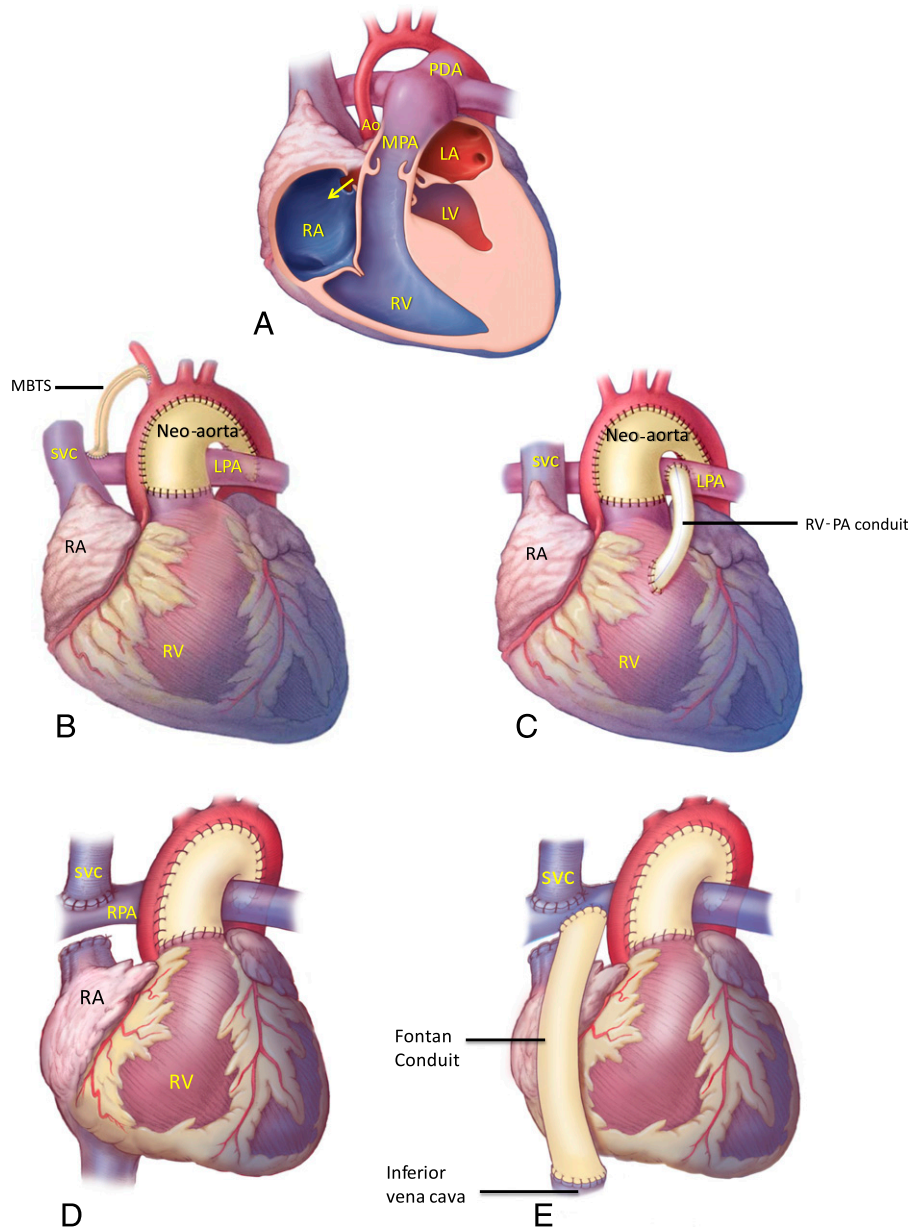
An essential component of normal intrauterine growth of cardiac structures is adequate blood flow through these structures. In HLHS, the mitral and aortic valves are either atretic or hypoplastic, thus decreasing the flow of blood through all left-sided heart structures (mitral valve, left ventricle [LV], aortic valve, and ascending aorta). In utero progression of aortic valve stenosis is one of the integral causes of HLHS. (15) Although bicuspid aortic valve is considered the mildest form of left-sided obstructive lesions, HLHS is at the most extreme end of the spectrum.

Premature closure of the foramen ovale, or other abnormalities of the atrial septum that restrict inflow to the left side of the heart, can be another cause of HLHS. (16) As a result of reduced flow of blood into the left atrium and the LV, the left heart structures do not grow. In late gestation, when HLHS is fully manifest, the flow of blood is from the left atrium to the right atrium across the atrial septum. In the most severe form, the atrial septum is intact. In that case, there is no egress of blood from the left atrium, resulting in pulmonary venous obstruction and hypertension. This impairs development of the pulmonary vasculature in utero and is associated with pulmonary hypertension and poor outcomes after birth.

## ANATOMY

HLHS consists of a spectrum of anatomical variants characterized by the underdevelopment of the left side of the heart, which includes the mitral valve, LV cavity, LV outflow tract, aortic valve, ascending aorta, and aortic arch (Fig A). The 3 most common forms are as follows:

1. Aortic valve atresia with mitral valve atresia: This is the most extreme form of HLHS in which the LV cavity is



**Figure.** A. The anatomy of hypoplastic left heart syndrome with underdeveloped left ventricle (LV). The arrow indicates the atrial septum defect. B. Stage 1 palliation using a modified Blalock-Taussig shunt (MBTS). C. Stage 1 palliation using a right ventricle (RV)-to-pulmonary artery (PA) conduit (Sano modification). D. Stage 2 palliation using the bidirectional Glenn shunt. It is a direct anastomosis of the superior vena cava (SVC) to the right PA (RPA). E. Stage 3 palliation. The extracardiac Fontan uses a tube graft to connect the inferior vena cava to the central PA. Ao=aorta, LA=left atrium, LPA=left pulmonary artery, MPA=main pulmonary artery, PDA=patent ductus arteriosus, RA=right atrium.

very small (almost slitlike) and the ascending aorta and aortic arch are extremely hypoplastic. There is no LV output, so the sole source of blood supply to the systemic circulation is the RV through the PDA.

2. Aortic valve atresia with mitral valve hypoplasia: Due to aortic atresia, the ascending aorta and aortic arch are hypoplastic and the systemic flow again depends on the PDA. The mitral valve is patent and blood enters the LV, but there is no egress. The LV hypertrophies because it

contracts against an atretic aortic valve. The thick LV has an ischemic endomyocardium that can result in thick fibrotic tissue known as *endocardial fibroelastosis*. The LV cavity is hypoplastic but its mass can be greater than the first HLHS subtype, resulting in distortion of the RV inflow and tricuspid valve insufficiency.

3. Aortic valve stenosis with mitral valve hypoplasia: As opposed to aortic atresia, stenosis of the aortic valve does permit some egress of blood from the LV, resulting in

less hypoplasia of the LV, ascending aorta, and aortic arch.

Approximately 6% of patients with HLHS have an intact or severely restrictive atrial septum. This morphologic variant is associated with the worst outcome. (17)(18) The restrictive flow of blood across the atrial septum results in high left atrial pressure, resulting in abnormal development of the pulmonary vasculature.

Postnatally, the systemic circulation depends on the presence of adequate interatrial communication and the patency of the ductus arteriosus. The systemic circulation is ductal dependent, and the aortic arch, ascending aorta, and coronary arteries are perfused by reverse or retrograde flow of blood from the PDA. Prostaglandin E<sub>1</sub> (PGE<sub>1</sub>) infusion is essential for these newborns to ensure ductal patency.

## DIAGNOSIS AND PRESENTATION

HLHS can be diagnosed prenatally by obstetrical ultrasonography at 18 to 24 weeks. This ultrasonography can identify cardiac malformations that alter the 4-chamber view of the heart. If the left side of the heart appears abnormal, a referral for fetal echocardiography is indicated. A fetal echocardiogram, performed by a pediatric cardiologist, allows detailed ultrasonography that focuses on all the components of the fetal heart. The fetal diagnosis of HLHS depends on the operator's expertise. (19)

The clinical presentation of HLHS depends on the patency of the ductus arteriosus and the degree of restriction of the atrial septum. Neonates with HLHS who were not detected prenatally will present with clinical symptoms or abnormal pulse oximetry screening. This newborn pulse oximetry screen is recommended by the American Academy of Pediatrics and aims to detect critical congenital heart diseases before hospital discharge. A recent study shows that due to the implementation of state newborn screening policies, early infant deaths from critical congenital heart diseases have decreased by 33.4%, with an absolute decline of 3.9 deaths per 100,000 births. (20)

Neonates with a restrictive interatrial communication or intact atrial septum will exhibit cyanosis, respiratory distress, and signs of hemodynamic instability within the first few hours of after birth. Left atrial hypertension leads to pulmonary congestion and early onset of respiratory distress. These neonates require prompt intervention to relieve interatrial obstruction. Intrauterine procedures can also be performed if a prenatal diagnosis of restrictive/intact atrial septum is established. Attempts to create an adequate atrial septal defect in utero have met with varied success. (21)

Some newborns have an adequate interatrial communication, but the patency of the ductus arteriosus is not maintained. These patients usually present within the first week after birth with signs of systemic hypoperfusion manifested as shock, tachycardia, diminished peripheral pulses, and oliguria, which can be addressed with prompt administration of PGE<sub>1</sub>.

Neonates who have a sufficient interatrial communication and a persistent PDA continue to have adequate systemic perfusion and may initially appear normal. These neonates become symptomatic in the first few weeks after birth, usually after hospital discharge. As the pulmonary vascular resistance declines, they develop signs of pulmonary overcirculation manifested as tachypnea, poor feeding, and cyanosis.

Auscultation typically reveals no murmur. The second heart sound is single and loud due to the absence of an aortic valve component and closure of the pulmonary valve against systemic pressure. A flow murmur across the pulmonary valve can be heard. If there is significant tricuspid regurgitation, it is manifest by a holosystolic murmur.

An electrocardiogram is usually not specific but can show right axis deviation and RV hypertrophy. Similarly, chest radiographs are nonspecific and can show cardiomegaly and pulmonary venous congestion, depending on the degree of left atrial hypertension.

Transthoracic echocardiography is the definitive diagnostic test for HLHS. Depending on the anatomical variant, the echocardiographic views will demonstrate a dilated RV and features of HLHS. To devise a management plan for each patient, echocardiography soon after birth is required to determine the presence of an adequate atrial septal defect and the patency of the ductus arteriosus. In addition, detailed evaluation of the remaining cardiac anatomy and myocardial function is essential for management planning.

## MANAGEMENT

The initial management of a patient with HLHS aims to secure ductal patency with a PGE infusion. Depending on the clinical presentation, volume replacement/resuscitation, diuretics, and/or inotropes may be required. Patients with a restrictive or intact atrial septum will need enlargement/creation of an atrial septal defect. (22) This can be performed surgically or via a transcatheter approach.

Current management strategies for infants with HLHS are 3-stage surgical palliation, primary heart transplant, or comfort care. Due to many advances in surgical techniques and medical therapies for patients with HLHS, offering comfort care in the current era to parents of these patients

has become less common and remains debatable. (23) Due to the scarcity of organs for transplant, the preferred initial management for HLHS is staged surgical palliation.

The final objective of the 3-stage palliative operations is a Fontan operation. Fontan circulation consists of a single RV as the pump for systemic circulation and passive systemic venous flow for pulmonary perfusion. The goal of the surgical palliation is to achieve an adequate source of pulmonary blood flow, unobstructed coronary artery blood flow, a ductal independent systemic circulation with alleviation of cyanosis, relief of atrial-level obstruction, elimination of pulmonary arterial stenosis, and preservation of RV function.

### Stage 1 (Norwood or Hybrid Procedures)

Stage 1 palliative surgery in HLHS is performed in the first week after birth. It aims to provide the RV an unobstructed systemic circulation and establish controlled and balanced flow to the pulmonary circulation.

Oxygenated blood reaches the left atrium from the pulmonary veins. Resection of the atrial septum is performed to establish unhindered flow from the left atrium to the right atrium. The hypoplastic aortic arch is reconstructed with a homograft patch. The main pulmonary trunk is resected, and its proximal part is connected to the ascending aorta. This procedure is sometimes referred to as Damus-Kaye-Stansel. The defect in the distal pulmonary artery (PA) is closed. This allows RV flow to the systemic circulation.

In a classic Norwood procedure, flow to the pulmonary circulation is established by placing a modified Blalock-Taussig shunt (MBTS) from the innominate artery to the PA (Fig B). The MBTS shunt is also known as the modified Blalock-Thomas-Taussig shunt to signify the work contributed by Vivian Thomas. (24) It is constructed with a prosthetic tube. In ideal situations, the MBTS controls flow to the lungs and prevents pulmonary overcirculation and allows adequate delivery of blood to the pulmonary circulation.

One of the disadvantages of the MBTS is that it causes diastolic diversion of blood from the systemic circulation to the pulmonary circulation, negatively affecting the coronary circulation and possibly leading to myocardial ischemia. To overcome this "coronary steal" phenomenon, an alternative to the MBTS was developed. The "Sano modification" creates a tubular connection from the RV to the PA (Fig C). The Sano modification has its own potential disadvantages, with theoretical concerns for arrhythmias or aneurysm formation at the ventriculotomy site.

A multi-institution randomized clinical trial was conducted to assess the results of stage 1 palliation with MBTS versus RV-PA shunts. Investigators in this trial reported that

transplant-free survival 12 months after surgery was better with the RV-PA shunt than with the MBTS. However, beyond 12 months of age, no significant difference was observed for either procedure, (25) and there was a higher rate of repeated cardiovascular intervention in patients with the RV-PA shunt.

In high-risk patients with HLHS with preoperative organ dysfunction or infection, where cardiopulmonary bypass should be avoided, a "hybrid" approach is available that uses transcatheter and surgical approaches to achieve the goals of stage 1 palliation. (26) In the hybrid approach, PA bands are placed to limit the pulmonary flow, and a stent is deployed to maintain the ductal patency and ensure flow to the aorta. If required, adequate interatrial communication is established by stent placement or balloon septostomy of the atrial septum. (27) This approach offers benefits to high-risk patients by avoiding the deleterious effects of cardiopulmonary bypass in the newborn period. Issues with this procedure include maintaining ductal stent patency and obstruction of retrograde flow in the aortic arch. Studies are being conducted to assess the outcome of this approach in patients with different risk factors. (28) After stage 1 operation, the systemic oxygen saturation is usually in the 70% to 85% range.

### Interstage Monitoring

To improve outcomes after stage 1 palliation, an interstage monitoring program of oxygen saturation and weight is designed for home use. Many patients are discharged from the hospital with a digital scale and pulse oximeter, and parents are advised to obtain daily weights and oxygen saturations. The monitoring program is designed for early recognition of decreased oxygen saturation from baseline and poor weight gain or weight loss. Parents are advised to notify their primary care provider in case of dropping oxygen saturation and failure to gain weight or weight loss. The primary care provider is a vital component of interstage monitoring, and frequent evaluations and communication with a member of the cardiac team are essential for prompt investigations and interventions to rule out complications.

In one study, 157 patients who underwent stage 1 palliation were discharged with home monitoring. Interstage survival was found to be 98%. Fifty-nine percent of the patients in this home monitoring program breached the surveillance criteria. (29) Interstage survival after stage 1 palliation has improved, (30) but there is debate about improvement in long-term survival because many high-risk patients remain in the hospital for prolonged periods between stages 1 and 2. (31)

### Stage 2 (Bidirectional Superior Cavopulmonary Connection)

The second stage of palliative surgery for HLHS is performed when patients are 3 to 6 months old. At stage 2, the previous shunt is removed and an anastomosis of the SVC to the right PA is established in what is called a *bidirectional Glenn shunt*. (32) This enables venous blood in the SVC to directly enter the pulmonary circulation (Fig D). Alternatively, a hemi-Fontan procedure can be performed, in which the SVC is not disconnected from the atrium but a patch is placed to exclude SVC flow from entering the right atrium. This patch is eventually removed at the time of Fontan completion. This is a more extensive procedure but it facilitates and augments the subsequent Fontan procedure. (33) Any stenosis of the pulmonary arteries is repaired at this time. After the bidirectional Glenn shunt, systemic oxygen saturation levels are in the low 80%. By using the hybrid strategy as a first-stage palliation, arch reconstruction is deferred until second-stage surgery. Aortic arch reconstruction at this age can be more complex than a neonatal Norwood aortic reconstruction. (34)

### Stage 3 (Fontan Circulation)

The third palliative surgery in HLHS is performed between 18 months and 4 years of age. Choussat et al (1977) outlined selection criteria to define an ideal candidate for a Fontan procedure. (35) An ideal candidate for a Fontan procedure is older than 4 years, has mean PA pressure less than 15 mm Hg, and has pulmonary arteriolar resistance less than 4 Wood units/m<sup>2</sup>. Patients with a good long-term outcome after Fontan operation generally have normal systolic and diastolic ventricular function and not more than mild tricuspid regurgitation, and they maintain sinus rhythm. Unfortunately, many patients with HLHS struggle with these features of a “good Fontan.” However, recently, younger patients with HLHS are being moved toward the Fontan than what was initially described by Choussat et al.

The goal of Fontan circulation is to route blood from the IVC to the pulmonary arteries. In this way, all systemic venous blood flows directly into the pulmonary circulation, without being pumped, bypassing the heart. This flow is passive and depends on higher central venous pressure and lower pulmonary vascular resistance. Negative intrathoracic pressure during normal breathing facilitates this passive pulmonary perfusion. Moreover, the complex physiology of Fontan circulation also depends on the ventricular end diastolic pressure. Typically, the IVC is disconnected from the atrium, and a large-bore Gore-Tex (W. L. Gore & Associates GmbH, Feldkirchen-Westerham, Germany) tube graft is used to connect it to the central PA. This procedure

is known as an “extracardiac” Fontan (Fig E). In the alternative method, a lateral tunnel Fontan, a wall is created inside the right atrium connecting the IVC to the SVC and pulmonary arteries in the heart. Unfortunately, Fontan physiology has negative long-term effects on other organ systems that sometimes are not manifest for several decades. (36)

## COMMON PEDIATRIC PROBLEMS AT VARIOUS STAGES OF PALLIATION

### Feeding Problems

Patients with HLHS have a high metabolic and nutritional demand in the setting of major cardiac operations and wound healing. In addition, there are several periods of no enteral feedings due to sedation or high-dose vasopressors. These patients also experience a high incidence of necrotizing enterocolitis. Adequate caloric intake must be assessed and addressed every day in the hospital and on every outpatient clinic visit. Maximizing caloric intake is necessary to achieve normal growth. Because surgical intervention begins in the neonatal period and these patients experience prolonged ICU stays, feeding problems are very common in children with HLHS. The sedation needed for invasive procedures and the lack of oral stimulation frequently results in oral aversion. Early involvement of occupational therapy and bedside nursing focused on feeding issues can reduce this problem. Many patients may require tube feeding to ensure adequate caloric intake. Need for gastrostomy tube placement in this patient group is not uncommon. The Feeding Work Group of the National Pediatric Cardiology Quality Improvement Collaborative has conducted a literature review to assess the best nutrition practices in various participating centers to outline nutrition algorithms for infants with HLHS. (37)

### Dehydration

Children with HLHS can acquire gastrointestinal viral infections similar to any other child. However, they do not tolerate dehydration very well. In addition, many of these children are taking diuretics, and this makes them even more vulnerable to dehydration. After stage 1 surgery, dehydration may precipitate shunt occlusion. Although all children are treated prophylactically with aspirin, the MBTS or Sano shunt may thrombose in the setting of intravascular volume depletion due to sluggish blood flow. This may lead to decreased blood flow to the lungs, resulting in a profound hypoxia. A shunt murmur may not be audible in this situation, and an echocardiogram should be performed

emergently to assess shunt flow. An emergency surgical or transcatheter intervention may be needed to reestablish pulmonary perfusion. If the shunt is patent, euvolemia should be achieved by oral or intravenous fluid resuscitation.

After stage 2 and 3 surgery, dehydration should be avoided, but the presentation is not as dramatic or life-threatening. Hypovolemia after stage 2 and 3 leads to decreased central venous pressure. A relatively high central venous pressure is needed to have passive flow of blood from the venae cavae to the pulmonary circulation. Fluid resuscitation should be performed boldly, without fear of developing pulmonary edema in this setting.

### Respiratory Infections

Viral respiratory infections are common in children and can become life-threatening in those with HLHS. After stage 1 palliation, the balance between the pulmonary and systemic circulation is maintained by the size of the MBTS or Sano shunt and the pulmonary vascular resistance relative to the systemic vascular resistance. Pulmonary vascular resistance is increased with respiratory infections, disrupting this balance and resulting in hypoxia. Pulmonary vasodilation is used to reestablish this balance and alleviate hypoxia. Supplemental oxygen is the easiest and quickest way to achieve pulmonary vasodilation. Proper pulmonary toilet is essential. Mechanical ventilation with inhaled nitric oxide may be needed in severe respiratory compromise.

After stage 2 and 3 surgeries, the increase in pulmonary vascular resistance from respiratory infection has a slightly different hemodynamic effect and is managed slightly differently. However, it still presents with hypoxia. Here the passive pulmonary blood flow depends on low pulmonary vascular resistance. Therefore, the increase in pulmonary vascular resistance impairs pulmonary perfusion, resulting in hypoxia. Pulmonary vasodilation by administering supplemental oxygen, and sometimes inhaled nitric oxide, is used to decrease the pulmonary vascular resistance. Contrary to stage 1 surgical patients, intubation and positive pressure mechanical ventilation should be avoided if possible after Glenn and Fontan operations because negative intrathoracic pressure from normal breathing assists passive pulmonary perfusion after stages 2 and 3. In addition, intravenous fluid administration can also help with pulmonary perfusion by increasing the central venous pressure.

### Immunizations

Patients with HLHS are a high-risk population, and immunization is an essential part of their health-care. Respiratory tract infections, particularly respiratory syncytial virus (RSV)

and influenza, are a cause of morbidity and mortality during the interstage period in patients with HLHS. These patients require hospitalization, cardiopulmonary bypass, and blood component transfusion, and so it is very important for the primary care provider and cardiac team to coordinate time frames for their optimal immunization. Preventive measures and education of the families regarding hand hygiene and immunizations can play a major role in improving mortality and morbidity in this group. Inactivated influenza vaccine is recommended in all children older than 6 months. (38)(39) Regarding prophylaxis against RSV, administration of palivizumab in infants with HLHS should be made in consultation with a pediatric cardiologist. An individualized approach should be taken for each patient regarding their hemodynamic status and timings of the surgery. (40)(41) Routine immunization has not been reported to be associated with any adverse outcomes in these patients. (42) The National Pediatric Cardiology Quality Improvement Collaborative has led an initiative toward quality improvement in the interstage period, with one of the goals being to discuss and document immunization status and plan for RSV and influenza prevention at every clinic visit. (43)

### Neurodevelopmental Outcomes

Patients with HLHS are at high risk for neurodevelopmental delays and impaired brain growth and maturation. (44) The neurodevelopmental disabilities include changes in visual motor integration, motor and language deficits, and cognitive dysfunction. In evaluation of the school-aged children who had undergone staged palliation, an increase in the prevalence of attention-deficit/hyperactivity disorder was found. (45) Early recognition of the delays and longitudinal surveillance throughout childhood and into adulthood are necessary to prevent adverse outcomes in these patients. The guidelines for the neurodevelopmental care of children with congenital heart diseases are outlined by the American Heart Association. The guidelines recommend frequent systemic evaluations of the patients' developmental monitoring and recognition of the need for early interventions. (46)

### Antimicrobial Prophylaxis for the Prevention of Bacterial Endocarditis

According to the American Heart Association guidelines, last revised in 2007, patients with cyanotic or palliated cardiac conditions are at high risk for adverse outcome from infective endocarditis. (47) Therefore, before any dental procedure, antimicrobial prophylaxis for the prevention of bacterial endocarditis is suggested in patients with HLHS. This remains true even after Fontan operation.

## PROGNOSIS

Survival of patients with HLHS has improved during the past 3 decades. (48) Before development of the Norwood procedure, the only option was to provide comfort care to these patients. Hospital survival after stage 1 palliation has improved from 53% (1992–1996) to 93% (1996–2001). (49) However, the interstage (between stage 1 and 2 surgeries) mortality rate continues to be high. Those who make it to the Fontan procedure have better survival rates but are burdened by other long-term complications. (50) The long-term complications after Fontan procedure continue to be a major concern and are beyond the scope of this article. (36) Further efforts are required to decrease the morbidity and mortality associated with HLHS.

## Summary

- Based on strong research evidence, hypoplastic left heart syndrome (HLHS) is a critical congenital heart disease associated with high morbidity and mortality. (1)(4)
- Based on strong research evidence, the current management approach for infants with HLHS is 3-stage surgical palliation. The final objective of the 3 cardiac operations is to achieve Fontan circulation, consisting of a single right ventricle as the pump for systemic circulation, and passive pulmonary perfusion from the

systemic venous return. Patients with HLHS have complex and unique physiology after each surgical stage. (32)(48)(49)(51)

- Based on expert opinion, due to lack of relevant clinical studies, in patients who experience life-threatening respiratory infections, intubation and positive pressure mechanical ventilation should be avoided after Glenn and Fontan operations.
- Based on expert opinion, due to lack of clinical studies, a cautious approach is required to evaluate and treat dehydration in patients with HLHS. After stage 1 surgery, dehydration may precipitate shunt occlusion; therefore, fluid resuscitation should be accompanied by complete evaluation of the shunt.

## ACKNOWLEDGMENTS

The authors are grateful to the Todd and Karen Wanek Family Program for Hypoplastic Left Heart Syndrome for dedicating its efforts to improve the outcomes of patients with HLHS by introducing new diagnostic and therapeutic strategies. We also thank Dr David J. Driscoll, Division of Pediatric Cardiology, Mayo Clinic, Rochester, Minnesota, for reviewing this manuscript and making valuable suggestions for its improvement.

*References for this article are at <http://pedsinreview.aappublications.org/content/40/7/344>.*



## PIR Quiz

There are two ways to access the journal CME quizzes:

1. Individual CME quizzes are available via the blue CME link under the article title in the Table of Contents of any issue.
2. To access all CME articles, click "Journal CME" from Gateway's main menu or go directly to: <http://www.aappublications.org/content/journal-cme>.
3. To learn how to claim MOC points, go to: <http://www.aappublications.org/content/moc-credit>.

1. You are following in your clinic a 3-year-old boy with a history of hypoplastic left heart syndrome (HLHS). The patient is doing well and is being followed by cardiology. He underwent 2 stages of the 3-stage palliative surgical procedures. The mother informs you that she is 18 weeks pregnant and that the cardiologist has recommended a fetal echocardiographic screening to look for any type of associated congenital heart defect, not just HLHS. Of the following congenital heart defects, which is the most common defect that affects siblings or parents of patients with HLHS?
  - A. Bicuspid aortic valve.
  - B. Coarctation of the aorta.
  - C. HLHS.
  - D. Patent ductus arteriosus.
  - E. Tetralogy of Fallot.
2. A primigravida pregnant woman at 39 weeks' gestation is admitted to the labor and delivery suite in active labor. She had prenatal care and the baby was diagnosed as having HLHS on prenatal ultrasonography. In addition to the obstetrics team, the neonatologist, cardiologist, and NICU transport team are present during delivery. After 4 hours of labor she delivers a male newborn. In addition to the routine postdelivery interventions, which of the following measures is the most critical for the continued survival of this patient?
  - A.  $\beta$ -blocker infusion.
  - B. Echocardiography.
  - C. Indomethacin infusion.
  - D. Prostaglandin E1 (PGE1) infusion.
  - E. Twelve-lead electrocardiography.
3. The patient in question 2 was admitted to the NICU, placed on a monitor, and given PGE1. On physical examination the baby looks well-perfused, with no labored breathing. Heart examination reveals a loud single S2 and a grade III holosystolic murmur best heard over the tricuspid area. Which of the following is the best diagnostic test to confirm the diagnosis of HLHS in this patient?
  - A. Cardiac computed tomography.
  - B. Cardiac enzyme levels.
  - C. Electrocardiography.
  - D. Magnetic resonance angiography.
  - E. Transthoracic echocardiography.
4. The diagnosis of HLHS is confirmed in this patient. A family care conference was held to discuss the management plan options with the family. Which of the following is the most appropriate initial management plan in this patient?
  - A. Discharge the patient and intervene if signs of decompensation occur.
  - B. Heart transplant after 2 years of age.
  - C. Immediate heart transplant.
  - D. Supportive and comfort care until a suitable heart donor is found.
  - E. Three-stage surgical palliation, with the first stage to start at 1 week of age.

**REQUIREMENTS:** Learners can take *Pediatrics in Review* quizzes and claim credit online only at: <http://pedsinreview.org>.

To successfully complete 2019 *Pediatrics in Review* articles for *AMA PRA Category 1 Credit™*, learners must demonstrate a minimum performance level of 60% or higher on this assessment. If you score less than 60% on the assessment, you will be given additional opportunities to answer questions until an overall 60% or greater score is achieved.

This journal-based CME activity is available through Dec. 31, 2021, however, credit will be recorded in the year in which the learner completes the quiz.



2019 *Pediatrics in Review* now is approved for a total of 30 Maintenance of Certification (MOC) Part 2 credits by the American Board of Pediatrics through the AAP MOC Portfolio Program. Complete the first 10 issues or a total of 30 quizzes of journal CME credits, achieve a 60% passing score on each, and start claiming MOC credits as early as October 2019. To learn how to claim MOC points, go to: <http://www.aappublications.org/content/moc-credit>.

5. A 6-year-old boy is brought to the clinic for a health supervision visit. His medical history is significant for HLHS status post 3-stage surgical palliative procedures, the last of which was the Fontan procedure performed at 4 years of age. Which of the following health maintenance interventions is recommended in this patient?
- A. Avoid live virus vaccines.
  - B. Bacterial endocarditis prophylaxis before dental procedures.
  - C. Immunizations are contraindicated.
  - D. Restrict caloric intake due to lower activity level.
  - E. Restrict fluid intake to prevent fluid overload.

**Hypoplastic Left Heart Syndrome: An Overview for Primary Care Providers**  
Rabia Javed, Frank Cetta, Sameh M. Said, Timothy M. Olson, Patrick W. O'Leary and  
Muhammad Yasir Qureshi  
*Pediatrics in Review* 2019;40;344  
DOI: 10.1542/pir.2018-0005

**Updated Information & Services**

including high resolution figures, can be found at:  
<http://pedsinreview.aappublications.org/content/40/7/344>

**References**

This article cites 51 articles, 17 of which you can access for free at:  
<http://pedsinreview.aappublications.org/content/40/7/344.full#ref-list-1>

**Subspecialty Collections**

This article, along with others on similar topics, appears in the following collection(s):  
**Cardiology**  
[http://classic.pedsinreview.aappublications.org/cgi/collection/cardiology\\_sub](http://classic.pedsinreview.aappublications.org/cgi/collection/cardiology_sub)  
**Cardiac Surgery**  
[http://classic.pedsinreview.aappublications.org/cgi/collection/cardiac\\_surgery\\_sub](http://classic.pedsinreview.aappublications.org/cgi/collection/cardiac_surgery_sub)  
**Cardiovascular Disorders**  
[http://classic.pedsinreview.aappublications.org/cgi/collection/cardiovascular\\_disorders\\_sub](http://classic.pedsinreview.aappublications.org/cgi/collection/cardiovascular_disorders_sub)

**Permissions & Licensing**

Information about reproducing this article in parts (figures, tables) or in its entirety can be found online at:  
<https://shop.aap.org/licensing-permissions/>

**Reprints**

Information about ordering reprints can be found online:  
<http://classic.pedsinreview.aappublications.org/content/reprints>



## **Hypoplastic Left Heart Syndrome: An Overview for Primary Care Providers**

Rabia Javed, Frank Cetta, Sameh M. Said, Timothy M. Olson, Patrick W. O'Leary and  
Muhammad Yasir Qureshi

*Pediatrics in Review* 2019;40;344

DOI: 10.1542/pir.2018-0005

The online version of this article, along with updated information and services, is  
located on the World Wide Web at:

<http://pedsinreview.aappublications.org/content/40/7/344>

Pediatrics in Review is the official journal of the American Academy of Pediatrics. A monthly publication, it has been published continuously since 1979. Pediatrics in Review is owned, published, and trademarked by the American Academy of Pediatrics, 345 Park Avenue, Itasca, Illinois, 60143. Copyright © 2019 by the American Academy of Pediatrics. All rights reserved. Print ISSN: 0191-9601.

# American Academy of Pediatrics

DEDICATED TO THE HEALTH OF ALL CHILDREN®

